

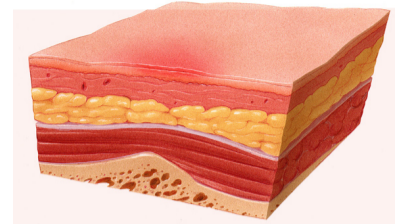
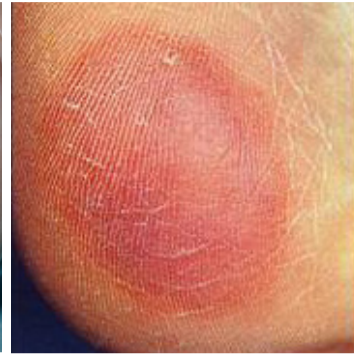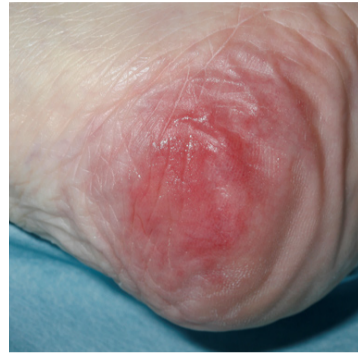Scottish Adaptation of the European Pressure Ulcer Advisory Panel (EPUAP) Pressure Ulcer Classification Tool

Early warning sign - Blanching erythema

Areas of discoloured tissue that blanch when fingertip pressure is applied and the colour recovers when pressure released, indicating damage is starting to occur but can be reversed. On darkly pigmented skin blanching does not occur and changes to colour, temperature and texture of skin are the main indicators.

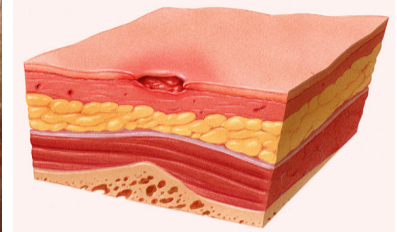
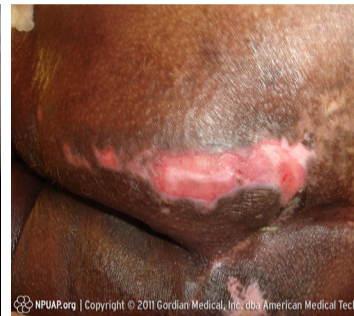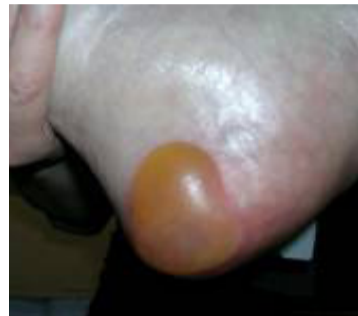Grade 1 - Non Blanchable Erythema

Intact skin with non-blanchable redness, usually over a bony prominence.
Darker skin tones may not have visible blanching but the colour may differ from the surrounding area.
The affected area may be painful, firmer, softer, warmer or cooler than the surrounding tissue.



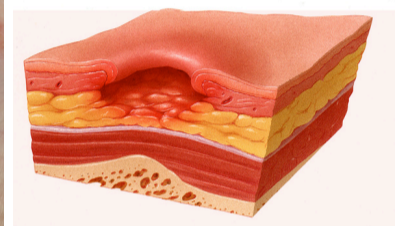
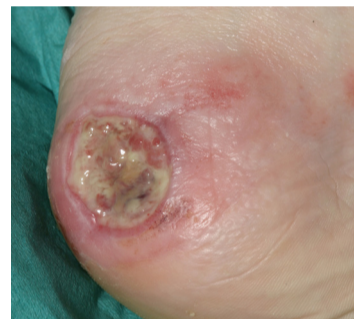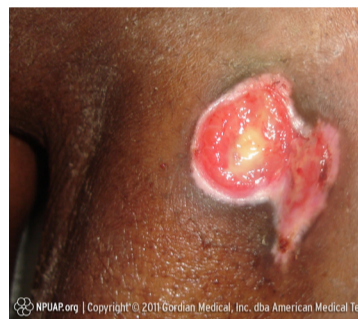Grade 2 - Partial thickness skin loss

Loss of the epidermis/dermis presenting as a shallow open ulcer with a red/pink wound bed without slough or bruising.*
May also present as an intact or open/ruptured blister.



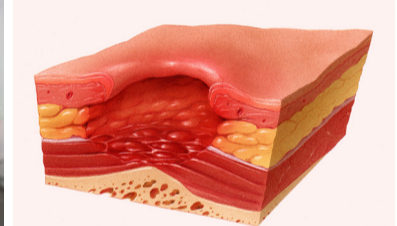
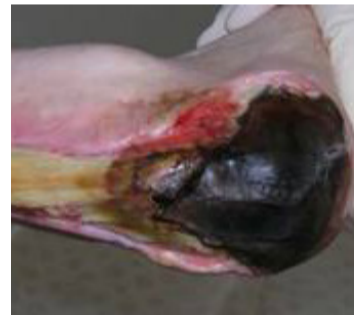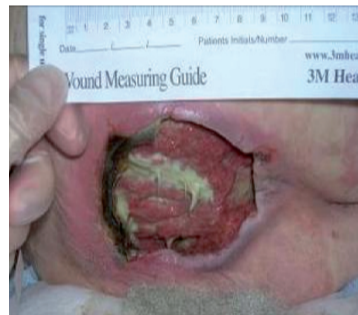Grade 3 - Full thickness skin loss

Subcutaneous fat may be visible but bone, tendon or muscle is not visible or palpable.
Slough may be present but does not obscure the depth of tissue loss. May include undermining or tunnelling.**



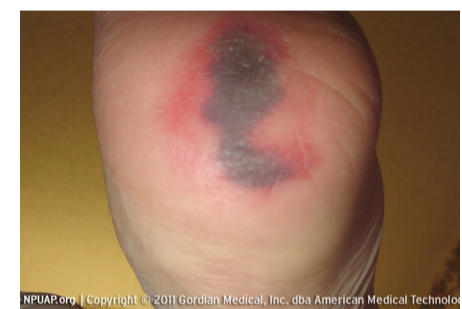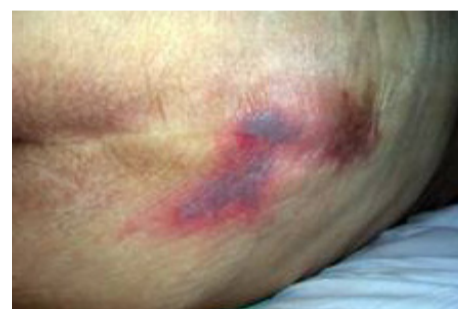Grade 4 - Full Thickness Tissue Loss

Extensive destruction with exposed or palpable bone, tendon or muscle. Slough may be present but does not obscure the depth of tissue loss. Often includes undermining or tunnelling.**



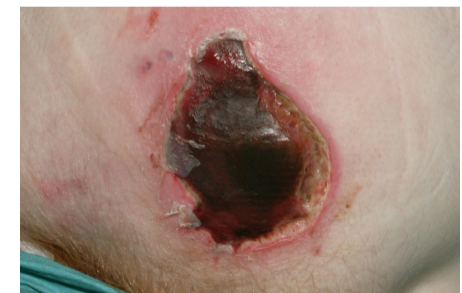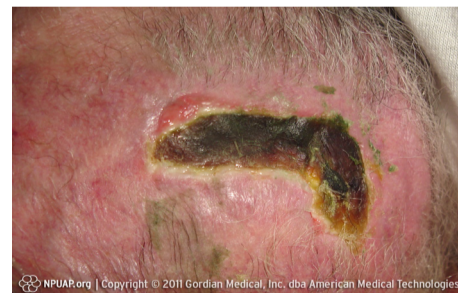Suspected Deep Tissue Injury:

Epidermis will be intact but the affected area can appear purple or maroon or be a blood filled blister over a dark wound bed. Some SDTI pressure ulcers resolve or stay static. Sometimes skin will degrade and develop into deeper tissue loss. Once grade can be established this must be documented.



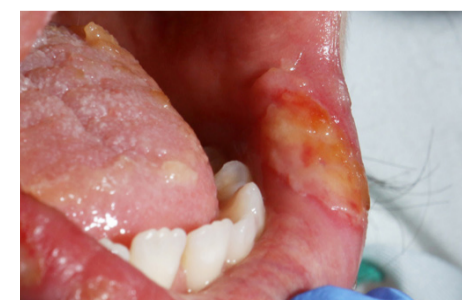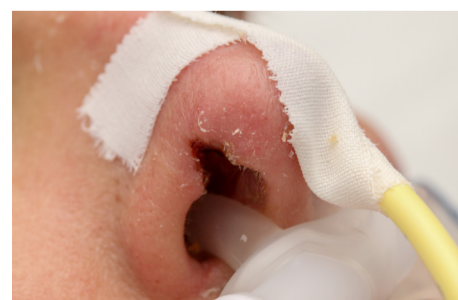Ungradable:

Full thickness skin / tissue loss where the depth of the ulcer is completely obscured by slough and / or necrotic tissue. Until enough slough and necrotic tissue is removed to expose the base of the wound the true depth cannot be determined. It may be a Grade 3 or 4 once debrided. Once grade can be established this must be documented.



Mucosal Pressure Ulcer:

These develop on mucosal membranes such as the tongue, mouth, nasal passages, genitals and rectum. Mucosal tissue does not have the same layers of skin as rest of the body so it cannot be graded and should be documented as a mucosal pressure ulcer.



*Bruising can indicate deep tissue injury

**The depth of a Grade 3 or 4 pressure ulcer varies by anatomical location. Areas such as the bridge of the nose, ears, occiput and malleolus do not have fatty tissue so the depth of these ulcers may be shallow. In contrast areas which have excess fatty tissue can develop deep Grade 3 pressure ulcers where bone, tendon, muscle is not directly visible or palpable.

Ref: Healthcare Improvement Scotland, Prevention and Management of Pressure Ulcers Standards 2020, NPIAP-EPUAP-PPPIA PRESSURE ULCER TREATMENT & PREVENTION 2019 QUICK REFERENCE GUIDE