



## CLINICAL GUIDELINE

# Diabetic Retinopathy Grading Scheme Scotland

A guideline is intended to assist healthcare professionals in the choice of disease-specific treatments.

Clinical judgement should be exercised on the applicability of any guideline, influenced by individual patient characteristics. Clinicians should be mindful of the potential for harmful polypharmacy and increased susceptibility to adverse drug reactions in patients with multiple morbidities or frailty.

If, after discussion with the patient or carer, there are good reasons for not following a guideline, it is good practice to record these and communicate them to others involved in the care of the patient.

<b>Version Number:</b>	6
<b>Does this version include changes to clinical advice:</b>	No
<b>Date Approved:</b>	12 <sup>th</sup> December 2022
<b>Date of Next Review:</b>	31 <sup>st</sup> December 2025
<b>Lead Author:</b>	Michael P Gavin
<b>Approval Group:</b>	Ophthalmology Clinical Governance Subcommittee

### Important Note:

The Intranet version of this document is the only version that is maintained. Any printed copies should therefore be viewed as 'Uncontrolled' and as such, may not necessarily contain the latest updates and amendments.

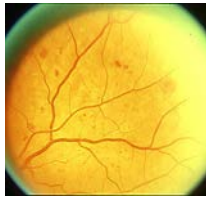## Scottish Diabetic Retinopathy Grading Scheme 2021 v4.0

The grading scheme is hierarchical and feature based. The grade for each eye is determined by the lowest grade compatible with the features present. Maculopathy is graded separately and in addition to the overall retinopathy grade.

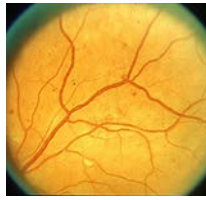Note that Grade R6 (not adequately visualised) should not be reported if despite poor image quality or visualisation, features sufficient to achieve a grade of R3, R4 or M2 can be identified, in which case ophthalmology referral is indicated.

Retinopathy	Description	Outcome
<b>R0</b> (no visible retinopathy)	<b>No diabetic retinopathy anywhere</b>	<b>Rescreen 12 months or 24 months*</b>
<b>R1</b> (mild)	<b>Background diabetic retinopathy BDR - mild</b> The presence of at least one of any of the following features anywhere <ul style="list-style-type: none"> <li>• dot haemorrhages</li> <li>• microaneurysms</li> <li>• hard exudates</li> <li>• cotton wool spots</li> <li>• blot haemorrhages</li> <li>• superficial/ flame shaped haemorrhages</li> </ul>	<b>Rescreen 12 months</b>
<b>R2</b> (observable background)	<b>Background diabetic retinopathy BDR - observable</b> Four or more blot haemorrhages (ie 2AH standard photograph 2a – see below) in one hemi-field only (Inferior and superior hemi-fields delineated by a line passing through the centre of the fovea and optic disc)	<b>Rescreen 6 months</b> (or refer to ophthalmology if this is not feasible)
<b>R3</b> (referable background)	<b>Background diabetic retinopathy BDR – referable</b> Any of the following features: <ul style="list-style-type: none"> <li>• Four or more blot haemorrhages (ie 2AH standard photograph 2a – see below) in both inferior and superior hemi-fields</li> <li>• Venous beading (2AH standard photograph 6a – see below)</li> <li>• IRMA (2AH standard photograph 8a – see below)</li> </ul>	<b>Refer ophthalmology</b> <i>These patients may be kept under surveillance and will not necessarily receive immediate laser treatment.</i>
<b>R4</b> (proliferative)	<b>Proliferative diabetic retinopathy PDR</b> Any of the following features: <ul style="list-style-type: none"> <li>• Active new vessels</li> <li>• Vitreous haemorrhage</li> </ul>	<b>Refer ophthalmology</b> <i>These patients are likely to receive laser treatment or another intervention.</i>
<b>R6</b> (inadequate)	<b>Not adequately visualised :</b> Retina not sufficiently visible for assessment	<b>Technical failure</b> <i>Arrange alternative screening examination. This will be automatic within the screening programme.</i>

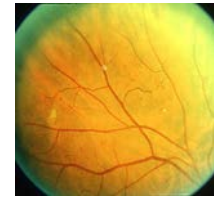**PHOTO 2a**



**PHOTO 6a**



**PHOTO 8a**

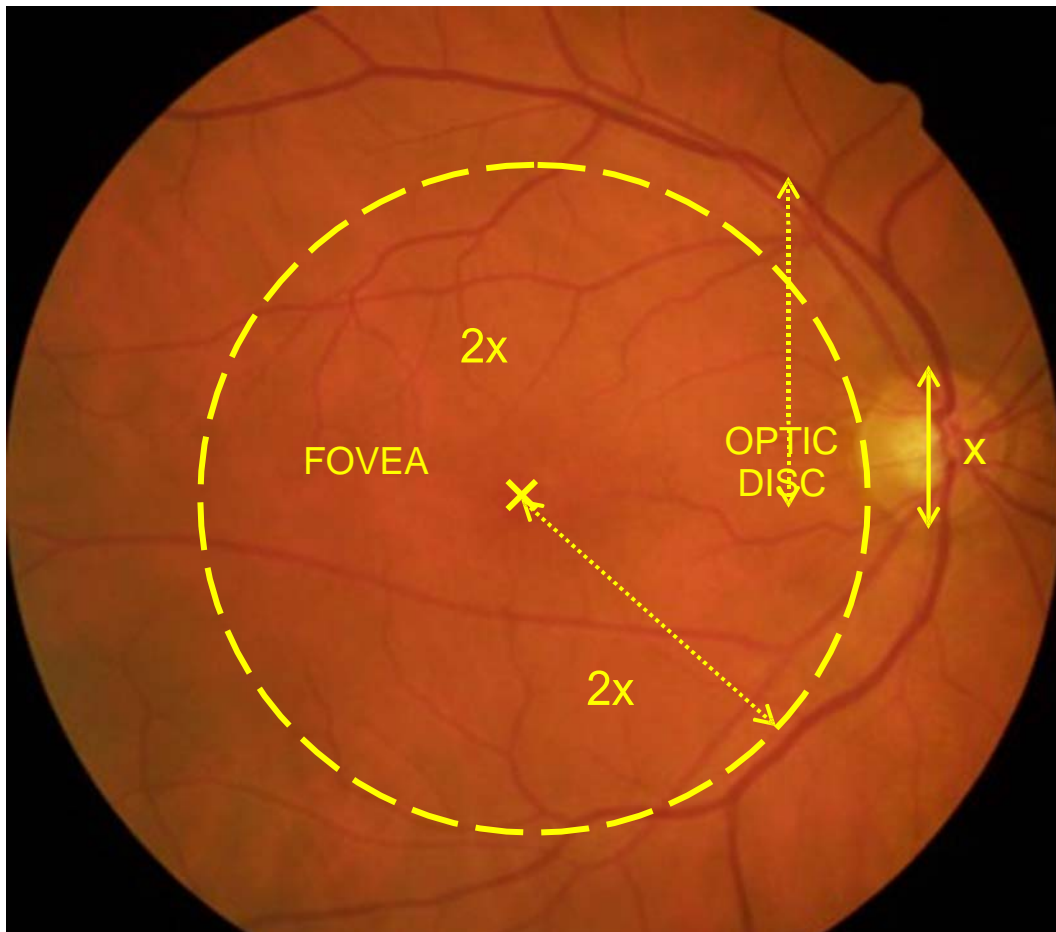


Maculopathy	Description	Outcome
<b>M0</b> (No maculopathy)	No features :: 2 disc diameters from the centre of the fovea sufficient to qualify for M1 or M2 as defined below.	<b>Rescreen 12 months</b>
<b>M1</b> (Observable)	Lesions as specified below within a radius of > 1 but :: 2 disc diameters the centre of the fovea <ul style="list-style-type: none"> <li>• Any hard exudates</li> </ul>	<b>Rescreen 12 months (Previously 6m)</b>
<b>M2</b> (Referable)	Lesions as specified below within a radius of :: 1 disc diameter of the centre of the fovea <ul style="list-style-type: none"> <li>• Any hard exudates</li> </ul>	<b>Refer for OCT scan** or 6 month rescreen</b>  <i>These patients may be kept under surveillance and will not necessarily receive immediate treatment.</i>

Coincidental findings	Description	Outcome
<b>Photo-coagulation</b>	<b>Laser photocoagulation scars present</b>	
<b>Other</b>	<b>Other non-diabetic lesion present:</b> <ul style="list-style-type: none"> <li>• Pigmented lesion (naevus)</li> <li>• Age-related macular degeneration</li> <li>• Drusen maculopathy</li> <li>• Myelinated nerve fibres</li> <li>• Asteroid hyalosis</li> <li>• Retinal vein thrombosis</li> </ul>	

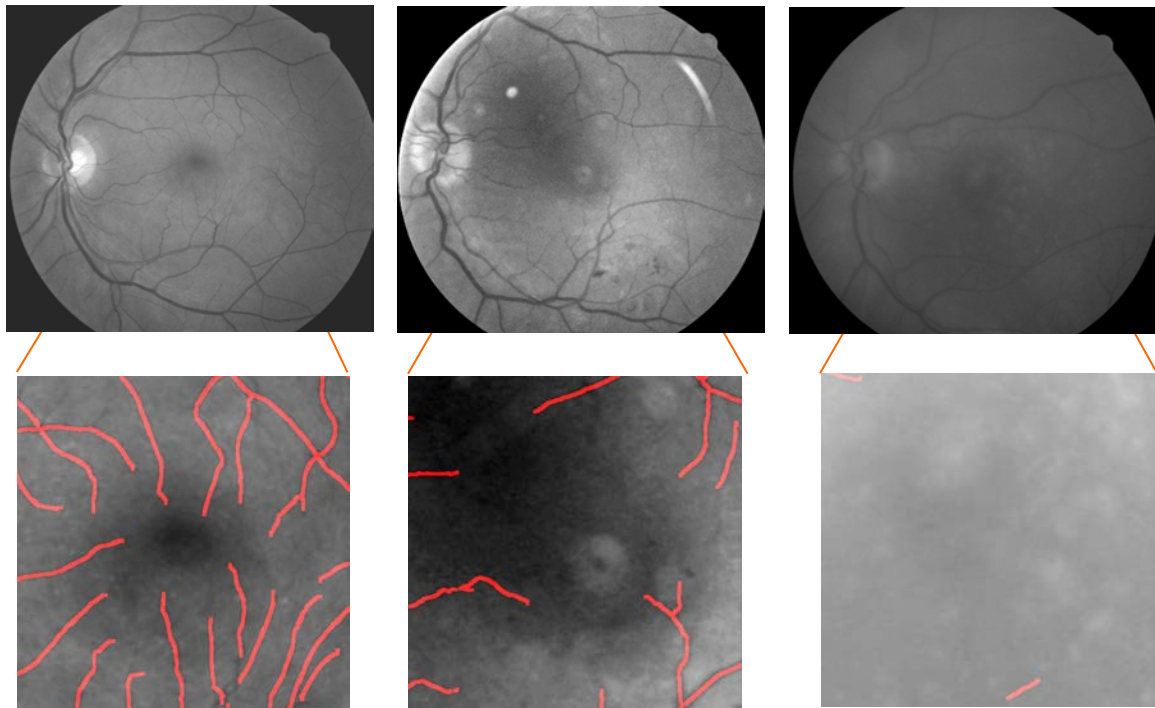
## Image Quality Definition

1. An image with visible referable retinopathy or maculopathy is always an adequate image for the purposes of grading.
2. An image that has adequate quality for grading has both adequate field definition (“has the correct area of retina been photographed?”) and adequate clarity (“would referable retinopathy and maculopathy be identified, if present”).
  - 2.1 An image with adequate field definition displays the intended macula-centred 45° portion of the retina
    - 2.1.1. The entire optic disc must be displayed
    - 2.1.2. The fovea must be at least 2.0 DD from the edge of the image.



2.2. An image with adequate image clarity allows referable retinopathy and maculopathy to be identified, if present.

2.2.1. The third generation vessels radiating around the fovea must be visible.



\*As from January 2021, patients with R0,M0 grade at their previous 2 consecutive annual visits will move to a 24 month screening interval.

\*\*AS from January 2021, patients with M2 grade and R0, R1 or R2 and VA at or below (worse than) 6/9.5 will have OCT imaging performed to determine if referral to HES is necessary. If VA is above (better than) 6/9.5 they will just be rescreened in 6 months.